

GROSS AND HISTOLOGICAL OBSERVATIONS ON THE LUNGS OF DOMESTIC PIGEON (*COLUMBA LIVIA DOMESTICA*)

Reda Mohamed^{1,2*}, Khaled Mazher³

¹Department of Basic Veterinary Sciences, School of Veterinary Medicine, Faculty of Medical Sciences, The University of the West Indies, St. Augustine, Republic of Trinidad and Tobago

²Department of Anatomy and Embryology, Faculty of Veterinary Medicine, Beni-Suef University, Beni-Suef 62511, Egypt

³Department of Cytology and Histology, Faculty of Veterinary Medicine, Beni-Suef University, Beni-Suef 62511, Egypt

Abstract. The main purpose of this study was to give detailed information about the anatomical and histological image aspect of the lungs in the domestic pigeons. Twenty (10 males and 10 females) adult domestic pigeons weighing 400-500 g. were used. The pigeons were slaughtered and their body cavity was opened to detect in situ position of the lungs. The trachea, syrinx, primary bronchi and lungs were dissected out and photographed. Lung tissue was taken and fixed in 10% formalin for 24-48 and then subjected to the routine histological procedure to produce slides which were stained by hematoxylin and eosin stain and then examined by the light microscope. The anatomical study revealed that the lungs of the domestic pigeon appeared as a pyramidal organs. They extended from the first to the six ribs. Each lung has costal, ventral and vertebral surfaces, lateral and medial borders as well as cranial and caudal margins. The costal surface was marked by six deep grooves. The lungs were surrounded by the capsule from which trabeculae divided the parenchyma into lobules. The entire lumen of parabronchi was surrounded by the openings of the atria.

Keywords: Anatomy, histology, lung, birds.

***Corresponding Author:** Reda Mohamed, Department of Basic Veterinary Sciences, School of Veterinary Medicine, Faculty of Medical Sciences, The University of the West Indies, St. Augustine, Republic of Trinidad and Tobago, Phone: 18686857804, e-mail: kkidareda@gmail.com

Received: 9 June 2020;

Accepted: 23 July 2020;

Published: 20 August 2020.

1. Introduction

Respiration is important for metabolic activity of a living organism which mediates oxygen transport to tissues and removes accumulated carbon dioxide from them (Kırbaş Doğan & Takıcı, 2018). The pigeon is a member of the bird family Columbidea and are kept as ornamental birds, messenger birds and for meat production (Gibbs *et al.*, 2007). Pigeons have special adaptation, they have an ingluvius which stores food temporarily and produces pigeon's milk for their nestlings (Weichert, 1959). The respiratory system of birds differs significantly from that of mammals and has an important role in making a sound, thermoregulation and gas purification (Gerrit & Clark, 1972; Pesek, 2000; Dewangan, 2011). It includes specific organs which are unique to the birds such as the syrinx and air sacs (Akester, 1960; Dyce *et al.*, 2000). The trachea bifurcates into two primary bronchi at the level of the syrinx where they enter the lungs (Al-Mahmodi, 2012; Al-Mussawy, 2011). The primary bronchus passes via its corresponding lung and it continues to the abdominal air sac via its caudal border (Frandsen *et al.*, 2009; Schachner *et al.*, 2009). The lungs of birds were seen as

unlobulated organs with costal impressions on their dorsal surfaces (Incei *et al.*, 2012; Serno *et al.*, 2008). The respiratory system of the pigeon consists of the trachea, two bronchi on syrinx and lungs which are completed by 9 air sacs (Brotowidjoyo, 1993). Since pigeons have small lungs and a high metabolism, they need high levels of oxygen so their air sacs will expand and deflate during flying to allow the air to enter and exit the lungs (Baumel *et al.*, 1993). The present investigation was to provide detailed information about the anatomical and histological structure of the lungs of domestic pigeons.

2. Materials and Methods

This current study was conducted on the pigeons after obtaining the ethical approval from the Beni-Suef University ethical committee. A total number of twenty (20) apparently healthy adult domestic pigeons (10 males and 10 females) weighing 400-500 g were used for the current study. The pigeons were purchased from the central market of Egypt and were transported to the anatomy laboratory of the faculty of veterinary medicine, Beni-Suef University, Egypt. The pigeons were slaughtered by cutting the blood vessels of the neck in a humane method. Defeathering was done and the birds were dissected by opening the coelomic cavity using a sharp dissecting scissors. The abdominal viscera were removed. The lower respiratory organs comprising of the trachea, extra pulmonary primary bronchi and lungs were studied grossly in situ and then were removed carefully and dissected by removing the remaining fat and connective tissue. Gross photos were taken using a Sony 12 megapixel digital camera (Sony Coporation, Japan). The tissue specimens were taken from the right and left lungs of the domestic pigeon and were fixed in 10% neutral buffered formalin for 24-48 hours. The fixed tissues were then processed routinely to prepare paraffin block by using paraffin embedding technique. The paraffin blocks were sectioned at 5 μ m thickness using rotary microtome and stained with Hematoxylin-Eosin (HE) for general morphological examination and Masson's Trichrome for detection of collagen fibers (Culling *et al.*, 1985). The stained sections were examined and photomicrographed by Olympus BX40 light microscope with an Olympus DP 15 megapixel digital camera, Japan).

3. Results

Gross observations

The trachea of the domestic pigeon was divided into two short extrapulmonary primary bronchi. The primary bronchi extended caudolaterally from the bronchiosyringeal cartilages of the syrinx to the corresponding lung. The lungs appeared as bright pink, pyramidal-shaped organs. They extended from the first to the sixth ribs. The lungs had three surfaces; the costal, ventral and vertebral surfaces, two borders; the medial and lateral borders and tow margins; the cranial and caudal. The costal surface was marked by six deep grooves which embedded in the first to the sixth ribs. Theses grooves separated the lung into five tori. The first cranial torus was the smaller then the other tori. The proximal third of the ventral surface had the hilus of the lung (Figure 1). There was no sexual dimorphism in the morphological structure of the lungs of the male and female domestic pigeons

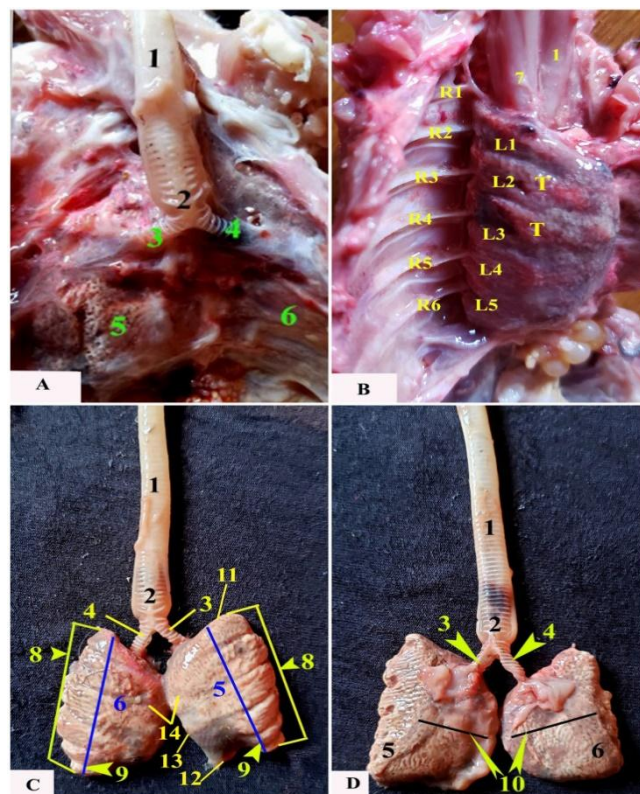


Fig. 1. Photographs showing the ventral view of the thoracic cavity in situ after removal of the heart (A & B) and the isolated lungs (C & D) of the domestic pigeon. 1-Trachea; 2- Syrinx; 3- Right primary bronchus; 4- Left primary bronchus; 5- Right lung; 6- Left lung; 7- Oesophagus; 8- Medial border of the lung; 9- Costal surface and impression of ribs; 10-Ventral (septal) surface of the lung; 11- Cranial margin of the lung; 12- Caudal margin of the lung; 13- Lateral border of the lung; 14-Vertebral surface; R (1-6)- Ribs; L(1-5)-Costal sulci; T-Intercostal torus

Microscopic observations

The lung of domestic pigeon appeared as a compact organ surrounded by fibroelastic connective tissue capsule. The parenchyma of the lung was formed of many lobules separated from each other by trabeculae in which bronchial tree and pulmonary blood vessels were branched. Each lung lobule was formed of a central parabronchus surrounded by intensive network of air capillaries. The parabronchus was lined by simple columnar epithelium rested on delicate fibroelastic connective tissue, lamina propria, and thick smooth muscle fibers. Several funnel-shaped atria lined by simple squamous epithelium were open in the lumen of the parabronchus. The latter was surrounded by intensive network of air capillaries which joined the atria via infundibula. The air capillaries were lined by flattened attenuated simple squamous epithelium. Intensive network of blood capillaries were intermingled with the air capillaries. Collagen fibers were seen abundant in the lamina propria and intermingled with the smooth muscle fibers of the primary bronchus. However the density of the collagen fibers decreased in the parabronchi as well as wall of the atria and air capillaries (Figures 2 and 3).

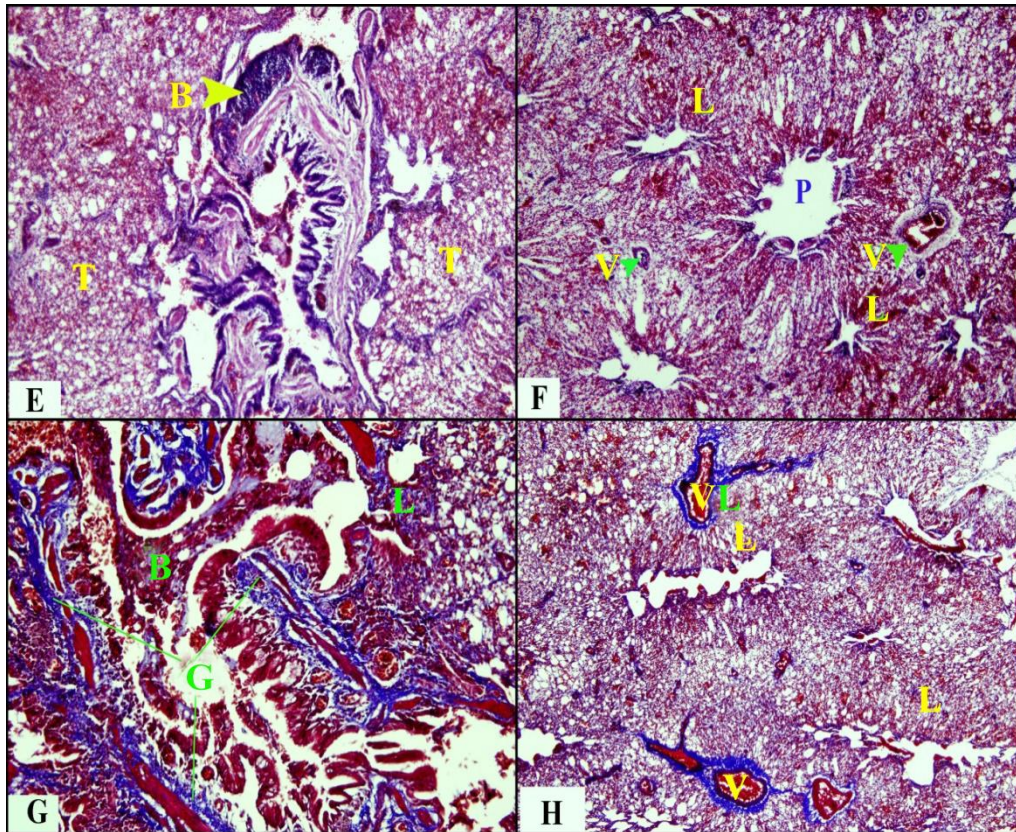


Fig. 2. Photomicrographs of the domestic pigeon lung showing the primary bronchus and respiratory tissue of the lungs. B-Primary bronchus; G- Collagen fibers; L- Lung lobules; P- Parabronchus; V. Pulmonary blood vessels; T-Lung tissue (H&E stain.X10 for E&F & Masson Trichrome Stain X 20 for G&X10 for H)

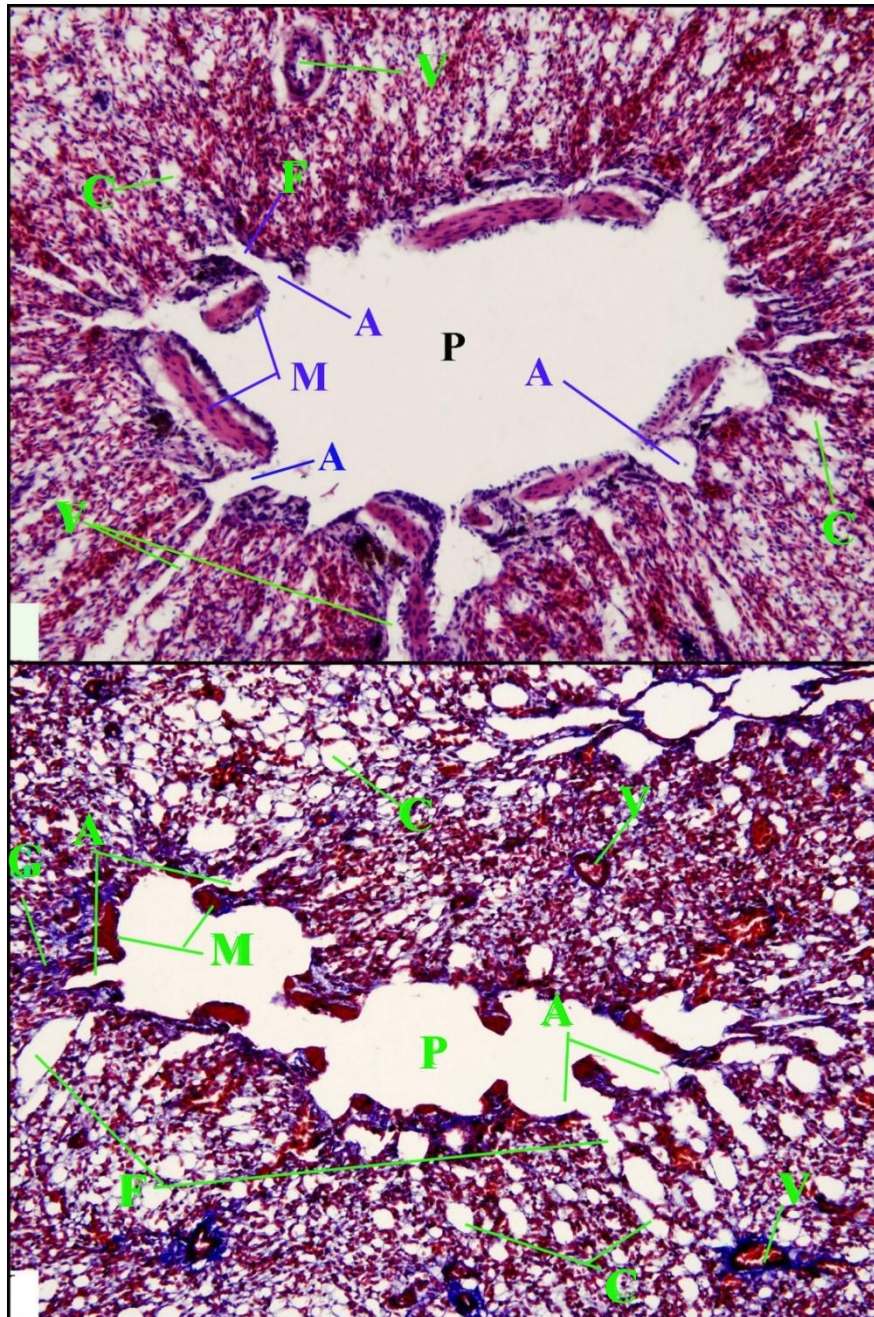


Fig. 3. Photomicrographs of the domestic pigeon lung showing the parabronchus. A- Atria; C- Air capillaries; F- Infundibula; G- Collagen fibers; M- Smooth muscles; P- Parabronchus; V. Pulmonary blood vessels (H&E stain.X40 for I& Masson Trichrome Stain X 40 for J)

4. Discussion

The current investigation revealed that the lungs of the domestic pigeon appeared as pink color, pyramidal-shaped organs which was similar to that reported in the *Columba domestica* pigeon (AL-Mahmodi, 2012), in the wood pigeon (Alumeri *et al.*, 2013), in the laughing dove (Al-Mamoori and Al-Abdulla, 2016), in the bee-eater bird (Al-Mamoori, 2014) and in the yellow-vented bulbul (Al-Ghakany, 2015). While, they appeared as bright red trapezium-shaped in the west African guinea fowl (Lbe *et al.*, 2008), elongated triangle shiny red in the turkey (AL-Mussawy, 2011) and either trapezium-shaped, elongated parallelogram or flattened rectangular structure in the duck, turkey, and chicken respectively (Getty, 1975), rectangular in chicken and triangular in duck and goose (König *et al.*, 2009).

The obtained results were parallel to those described in the *Columba domestica* pigeon (AL-Mahmodi, 2012), in the wood pigeon (Alumeri *et al.*, 2013) and the laughing dove (Al-Mamoori and Al-Abdulla, 2016) and in the bee-eater bird (Al-Mamoori, 2014) that the lungs of the domestic pigeon extend from the first to the sixth ribs, so that this inflexibility will increase the oxygen exchange surfaces throughout the avian respiratory cycle (Schachner *et al.*, 2009). The same findings were also reported in avian (Lbe *et al.*, 2008; Frandson *et al.*, 2009). On the other the hand, the lung of the yellow-vented bulbul extends from the first to the fourth rib (Al-Ghakany, 2015).

The present results achieved that the lung of the domestic pigeon had three surfaces; the costal, vertebral and ventral, a result which was in a line with that obtained in the *Columba domestica* pigeon (AL-Mahmodi, 2012), in the indigenous male turkey (AL-Mussawy, 2011) and in other avian species (McLelland, 1990; Baumel, 1993), while the lungs of the wood pigeon (Alumeri *et al.*, 2013), in the laughing dove (Al-Mamoori and Al-Abdulla, 2016), in the bee-eater bird (Al-Mamoori, 2014) and in the yellow-vented bulbul (Al-Ghakany, 2015) have the costal and visceral surfaces. On the other hand, the lung of the Japanese quail has costal, medial and ventral surface (Demirkan *et al.*, 2006) and in chicken and turkey which have the visceral surface (Maina, 2000).

The observation in this study was similar to that in the wood pigeon (Alumeri *et al.*, 2013) that the left and right extrapulmonary primary bronchi were approximately equal. However, the right primary bronchus was relatively longer and narrower than the left one in indigenous male turkey (AL-Mussawy, 2011) and in ostriches (Mania, 2000; Schachner *et al.*, 2009).

The current results achieved that the parenchyma of the lung of the domestic pigeon was formed of many lobules separated from each other by trabeculae. Several funnel-shaped atria were opened in the lumen of the parabronchus. The atria led to the infundibula which led to air capillaries; a result was a line with that obtained in the wood pigeon (Alumeri *et al.*, 2013), in the local Indian pigeon (Deshmukh *et al.*, 2017) and in the Aseel and Vanarajia (Dewangan, 2011) as well as in different types of the birds (Pesek, 2000; Al-Mussawy, 2011; Mania, 2000, Demirkan *et al.*, 2006; Schachner *et al.*, 2009).

The results in this study achieved that the presence of the smooth muscle fibers of the parabronchi at the openings of the atria which might be to let the atrial opening to contract and relax during respiration process. Moreover, the collagen fibers was observed in the primary bronchus, parabronchus as well as the wall of the atria and air

capillaries, a result which was in a line with that obtained in domestic fowl (Maina *et al.*, 2010) and in the Aseel and Vanarajia (Dewangan, 2011).

5. Conclusion

The lungs of the domestic pigeon were pyramidal-shaped, unlobed, soft, bright pink organs. They were sunken in the position of the 1st to 6th thoracic vertebrae. The parabronchus was surrounded by an intensive network of air capillaries. Intensive network of blood capillaries were intermingled with the air capillaries. There was no marked sexual dimorphism in the gross and microscopic structures of the lungs in the male and female domestic pigeons.

References

- Akester, A.R. (1960). The comparative anatomy of the respiratory pathways in the domestic fowl (*Gallus domesticus*), pigeon (*Columba livia*) and domestic duck (*Anas platyrhynchos*). *Journal of Anatomy*, 94, 487-505.
- Al-Ghakany, S.S.A. (2015). Anatomical study of the primary bronchi and the lung in yellow-vented bulbul (*PycnonotusGoivier*). *International Journal of Advanced Research*, 3(11), 818-822.
- AL-Mahmodi, A.M. (2012). Macroscopic and morphometric studies of the extrapulmonary primary bronchi and lungs of the indigenous adult male pigeon (*Columba domestica*). *Kufa Journal for Veterinary Medical Sciences*, 3(1), 19-26.
- Al-Mamoori, N.A., Al-Abdula, M.A.A. (2016). Anatomical and morphometric study of the trachea, primary bronchi and lung in laughing dove (*Streptopelia Senegalensis*). *Journal for Veterinary Medical Sciences*, 7(2), 111-119.
- Al-Mamoori, N.A. (2014). Anatomical Study of the Primary bronchi and the Lung of the Bee-eater bird (*Meropsorientalis*). *Basrah Journal of Veterinary Research*, 1(2), 3-259.
- AL-Mussawy, A.M.M. (2011). Anatomical and histological study of major respiratory organs (larynx, trachea, syrinx, bronchi and lungs) in indigenous male turkey (*Meleagris gallopava*). M.V.Sc Thesis, *AL-Qadisiya Uni. Vet. Med. College*.
- Alumeri, S.K.W., Al-Mamoori, N.A., & Al-Bishtue, A.A., 2013. Grossly and microscopic study of the primary bronchi and lungs of wood pigeon (*Columba palumbus*). *Kufa Journal for Veterinary Medical Sciences*, 4(2), 72-79.
- Baumel, J.J., King, A.S., Breazile, J.E., Evans, H.E., & Vanda Berge, J.C. (1993). Respiratory system. In: *Hand book of Avian Anatomy Nomina*. Anatomica Avium 2nd (Ed): club. Cambridge, Massachusetts, p. 257-299.
- Brotowidjoyo, M.D. (1993). *Zoologi Dasar*. Jakarta: Erlangga.
- Culling, C.F.A., Allison, R.T., & Barr, P.J. (1985). *Cellular pathology technique*, 4th ed, Butterworth & Co. Publishing Ltd, p. 221-261.
- Demirkan, A.Ç., Kurtul, I., Haziroglu, R.M. (2006). Gross morphological features of the lung and air sac in Japanese quail. *The Journal of Veterinary Medical Science*, 68(9), 909-913.
- Dewangan, B.K. (2011). Comparative gross, histomorphological and histochemical studies on lungs of aseel and vanaraja breeds of poultry. M.V.Sc. Thesis, *Department of Veterinary Anatomy and Histology, College of Veterinary Science and Animal Husbandrrry, Anjora, Durg (C.G.) 491001, Indira Gandhi Krishi Vishwavidyalaya, Raipur*.
- Deshmukh, S.K., Gupta, S.K., Karmore, S.K., Barhaiya, R.K., Yadav, S.K., & Tomar, S.S. (2017). Histological studies on lungs of local Indian pigeon. *Veterinary Practitioner*, 18(2), 194-195.
- Dyce, K.M., Sack, W.O., Wensing, C.J.G. (2010). *Textbook of Veterinary Anatomy*. 4th ed. Elsevier Saunders, Saint Louis, p. 799-804.

- Frandsen, R.D., Wilke, W.L., & Fails, A.D. (2009). Poultry respiratory system. In: *Anatomy and Physiology of farm Animals* 7th (Ed): Wiley-Black Well, p. 471-474.
- Gerrit, P.K. and Clark, L.C. (1972). The lung and air-sac system of the common grackle. *The Auk*, 89, 817-825.
- Getty, R. (1975). *Aves respiratory system*. In: *Anatomy of domestic animals*. W.S. Saunders co. Philadelphia, p. 1884-1917.
- Gibbs, D., Eustace, B., & John (2007). *Guide to the pigeons and Doves of the world*. United Kingdom: Pica Press, p.624.
- Incei, N.G., Pazvant, G., Hasan, A. (2012). Anatomical features of the syrinx in sea gulls. *Ankara Univ. Vet. Fak. Derg.*, 59(1), 1-3.
- König, H.E., Korbel R., & Liebich, H. (2009). Avian anatomy: textbook and colour atlas.
- Kırbaş Doğan, K.G., & Takıcı, İ. (2018). Anatomy of respiratory system in poultry. *MAE Vet FakDerg*, 3 (2), 141-147.
- McLelland, J. (1990). Respiratory system. In: *a colour atlas of avian anatomy*. Wolfe Publishing Ltd. Eng, p. 95-119.
- Lbe, C.S., Onyeausi, B.I., Salami, S.O., Umosen, A.D., Maidawa, S.M. (2008). Studies of the major respiratory pathways of the West African guinea fowl (*Numidameleagrisgaleata*): The Morphometric and Macroscopic Aspects. *International Journal of Poultry Science*, 7(10), 997-1000.
- Maina, J.N. (2000). Comparative Respiratory Morphology: Themes and principles in the design and construction of the gas exchangers. *The Anatomical Record*, 26(1), 25-44.
- Maina, J.N., Jimoh, S.A., Hosie, M. (2010). Implicit mechanistic role of the collagen, smooth muscle, and elastic tissue components in strengthening the air and blood capillaries of the avian lung. *Journal of Anatomy*, 217, 597-608.
- Pesek, L. (2000). *The avian respiratory system*. Winged Wisdom Pet Bird Magazine. 1, 1-3.
- Schachner, E.R., Lyson, T.R., Dodson, P. (2009). Evolution of the respiratory system in no avian theropods: Evidence from rib and vertebral morphology. *The anatomical Record*, 292, 1501-1513.
- Weichert, C.K. (1959). *Elements of chordate anatomy*. Second Edition. New York: McGraw-Hill Book Company Inc.